



**PATIENT PRESENTING CLINICAL SIGNS**

**Buddy Palmer**  
History: PUO, lethargy.  
Physical Examination: Lymphadenomegaly, pyrexia, abdominal discomfort.  
**SPECIES**  
Feline  
Urinalysis: N/A.  
CBC: N/A.  
**BREED**  
DSH  
Serum Biochemistry: fPL positive.  
Radiographic Findings: N/A.

**SEX**

MN

**Age**

9 years

**ULTRASONOGRAPHIC EXAMINATION OF THE ABDOMEN**

**Urinary System**

Full urinary bladder with a normal thickness and appearance of the wall. Normal anechoic urine with no sediment or uroliths evident.

**WEIGHT**

9 kg

Normal trigone area, proximal urethra, and iliac blood vessels.

Normal iliac lymph nodes. Ureters not visualized.

**INTERPRETED BY**

Remo Lobetti, BVSc,  
MMedVet (Med), PhD, Dipl.  
ECVIM

Normal renal size (left 4.5 cm, right 4.4 cm), echogenic appearance, cortico-medullary differentiation, pelvis, and capsule.

**Reproductive System**

N/A.

**IMAGING PERFORMED BY**

Dr Kuzimski

**Adrenal Glands**

Normal position, echogenic appearance, shape, size.

**HOSPITAL NAME**

Animal Emergency Hospital  
Deland

**Spleen**

Normal size with a mottled echogenic and nodular appearance. Smooth homogenous parenchyma, regular curvilinear capsule, and normal vasculature.

**REFERRING VET**

Dr Kuzimski

**Liver**

Normal size, echogenic appearance, portal markings, and regular curvilinear capsule. No nodules or masses evident.

**INVOICE**

304075

**Gall bladder**

Full containing normal anechoic bile. Normal thickness and echogenic appearance of the wall. Normal bile duct.

**DATE**

4/4/23


**PATIENT** *Gastrointestinal*

Buddy Palmer Normal appearance of the stomach, duodenum, small intestine, ileo-cecal junction, and colon with no loss of layering, normal wall thickness (stomach 0.31 cm, jejunum 0.35 cm) and peristalsis, and no distension of the lumen.

**SPECIES**

Feline

*Pancreas*

Normal size with a hypoechogenic appearance and irregular capsule. Hyperechogenic echogenic appearance of the mesentery and fat surrounding the pancreas.

**BREED**

DSH

*Free Abdomen*
**SEX**

Mesenteric lymphadenomegaly (1.3 cm) with a rounded and hypoechogenic appearance. Hyperechogenic appearance of the mesentery surrounding the lymph nodes.

**MN**

No ascites evident.

**Age**

9 years

**ULTRASONOGRAPHIC FINDINGS**

Primary Findings:

- Splenic pathology.
- Mesenteric lymphadenomegaly.
- Pancreatitis.

**WEIGHT**

9 kg

**INTERPRETED BY**

Secondary Findings:

- None.

Remo Lobetti, BVSc,  
MMedVet (Med), PhD, Dipl.  
ECVIM

**IMAGING PERFORMED BY**

Dr Kuzimski

**INTERPRETATION OF THE FINDINGS & FURTHER RECOMMENDATIONS**

Etiologies for the lymph nodes and spleen would be reactive, lymphadenitis/splenitis, granulomatous disease, and infiltrative neoplasia.

**HOSPITAL NAME**

Further assessment would be FNA of the lymph nodes and spleen for cytology and culture.

Animal Emergency Hospital  
Deland

Specific therapy would be dependent on an etiological diagnosis.

**REFERRING VET**

Dr Kuzimski

**INVOICE**

304075

**DATE**

4/4/23



**PATIENT**

Buddy Palmer

**SPECIES**

Feline

**BREED**

DSH

**SEX**

MN

**Age**

9 years

**WEIGHT**

9 kg

**INTERPRETED BY**

Remo Lobetti, BVSc,  
 MMedVet (Med), PhD, Dipl.  
 ECVIM

**IMAGING PERFORMED BY**

Dr Kuzimski

**HOSPITAL NAME**

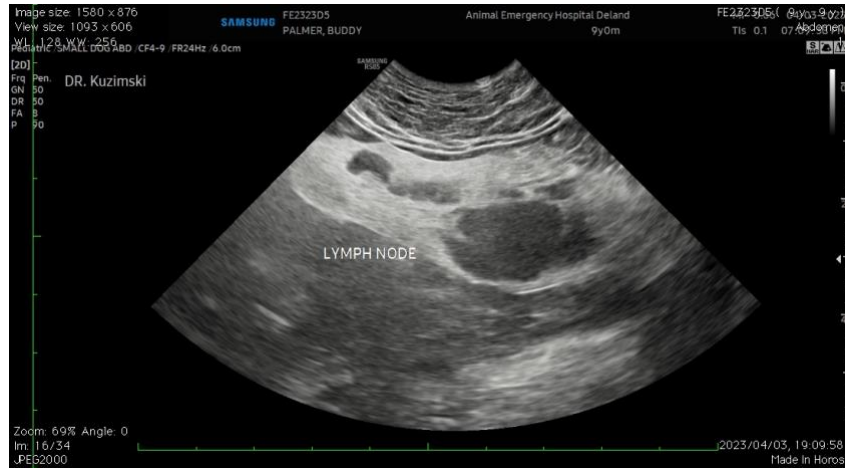
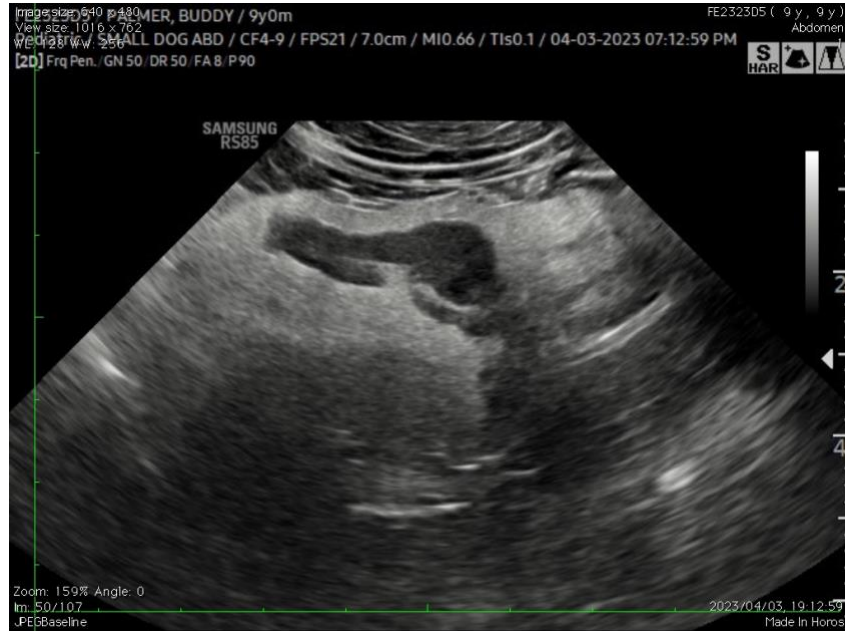Animal Emergency Hospital  
 Deland

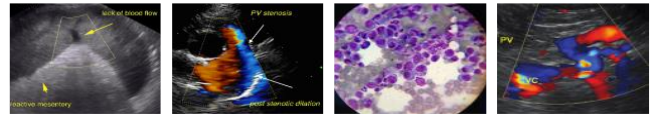
**REFERRING VET**

Dr Kuzimski

**IMAGES**

**Mesenteric lymph nodes**





**PATIENT** Spleen

Buddy Palmer

**SPECIES**

Feline

**BREED**

DSH

**SEX**

MN

**Age**

9 years

**WEIGHT**

9 kg

**INTERPRETED BY**

Remo Lobetti, BVSc,  
MMedVet (Med), PhD, Dipl.  
ECVIM

**IMAGING PERFORMED BY**

Dr Kuzimski

**HOSPITAL NAME**

Animal Emergency Hospital  
Deland

**REFERRING VET**

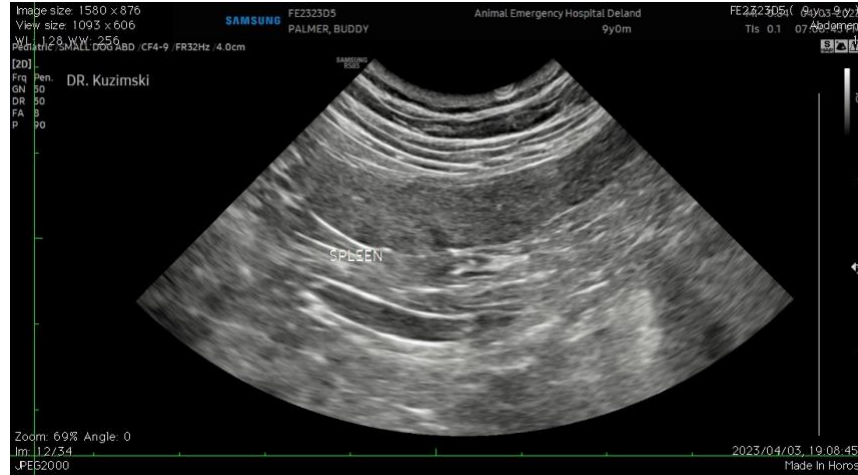
Dr Kuzimski

**INVOICE**

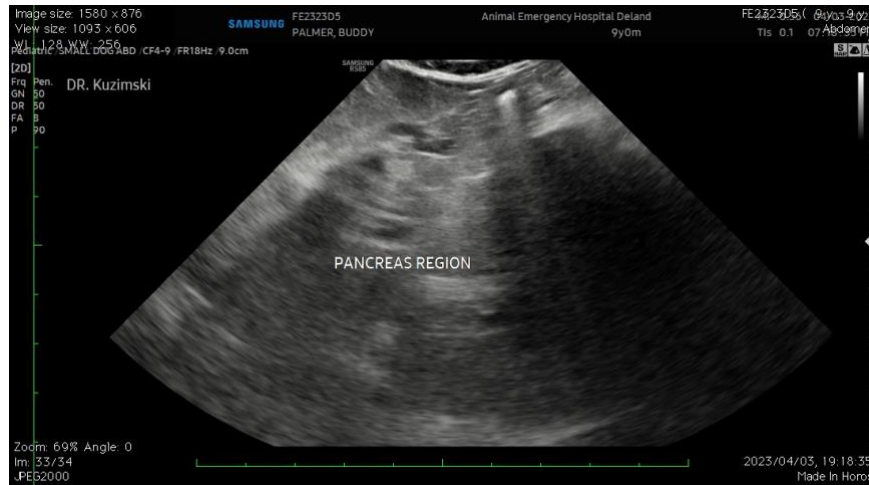
304075

**DATE**

4/4/23



**Pancreas**



**The information and recommendations provided are based on the images presented by the referring veterinarian. No evaluation can be communicated regarding pathology that was not visible in the image/video clips provided.**

Thank you for this referral. If the clinical or image interpretation does not parallel your findings or if I can be of any further assistance, please contact me.

**Remo Lobetti, BVSc, MMedVet (Med), PhD, Dipl. ECVIM (Internal Medicine)**  
[rlobetti@mweb.co.za](mailto:rlobetti@mweb.co.za)